

A METHOD PROVIDING COSMETIC RESTORATION FOR PARTIALLY EDENTULOUS PATIENTS WITH MISSING ANTERIOR TEETH

M. Hassabala, BChD, HDD, MScD*

معالجة المرضى المصابين بحدوث جزئي (غياب بعض الأسنان) مترافق بفقد للأسنان الأمامية تعتبر من إحدى المشكلات الجمالية التي تواجه طبيب الأسنان والطريقة المقدمة في هذا المقال تسمح لطبيب الأسنان، وفي الأسنان من تقييم وتعديل وتحسين صف الأسنان الأمامية للصفحة الجزئية في المراحل الأولى للمعالجة فبعد الانتهاء من صف الأسنان الأمامية نلجأ إلى تشميع هيكل الصفحة الجزئية تبعاً لوضع الأسنان الأمامية وبتابع ذلك نؤمن رابطة قوية لهذه الأسنان الأمامية ونتجنب إعادة تنظيم الأسنان الصناعية لتوافق هيكل الصفحة الجزئية المصنوب مع التقليل من احتمال ظهور المعدن والاساءة إلى الناحية الجمالية.

Treatment of partially edentulous patients with missing anterior teeth presents a specific cosmetic challenge to the dentist. The technique presented allows the dentist and the technician to evaluate, modify, and improve the esthetic arrangement of the anterior teeth in a removable partial denture early in the course of treatment. Once the position of the anterior teeth is established, the partial denture framework is waxed-up accordingly. Thus, ensuring a strong attachment of the anterior teeth, avoiding gross recontouring of the artificial teeth to fit the existing removable partial denture framework, and minimizing metal display.

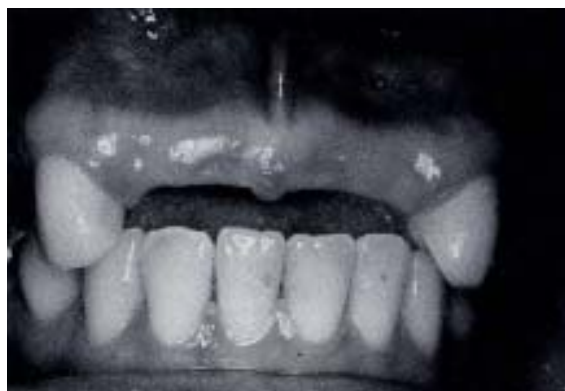Introduction

The majority of removable partial dentures make significant contribution to patient's appearance.¹ When restoring missing anterior teeth several challenging cosmetic and biomechanical problems must be managed properly [Fig. 1].

Treatment of partially edentulous patients with missing anterior teeth presents a specific cosmetic challenge since the replaced teeth are conspicuous and the lip/ridge morphologies that can be encountered vary greatly among patients.²⁻³

Fixed prosthetic restoration of missing anterior teeth is considered preferable to a removable one due to simplicity of design, favorable stress control, and psychologic advantage associated with its being fixed in place. Despite such preference, partially edentulous patients whose candidacy for dental treatment is questionable because of attitude or motivation are prescribed removable prosthodontic therapy. However, if the same

criteria that were used for patient selection for fixed prosthetic service were equally applied to patient selection for removable partial denture service, the myth of an association of removable partial dentures with a higher incidence of dentogingival disease would be refuted.²⁻⁴ In a biomechanical context, the superiority of one treatment over the other may be questionable. The extensive reduction of tooth structure for fixed prosthodontic abutment preparation coupled with permanent cementation of the prosthesis



Figure!. Partially edentulous patient with missing anterior teeth.

*Assistant Professor and Head, Division of Complete Denture Prosthodontics, Department of Prosthetic Dental Sciences, College of Dentistry, King Saud University, Riyadh, Saudi Arabia,

emphasizes the irreversible nature of fixed restorations and, thus, an inherent shortcoming.⁴ Thus, the use of a fixed or removable prosthesis does not, of itself, cause dentogingival disease. A high standard of oral hygiene will prevent caries, gingivitis, and destructive periodontal disease.^{5,7} If the removable partial denture service is placed in its correct cosmetic and biomechanical context, and implemented in a way that not only restores the mouth but also minimizes potential damage to the supporting structures, then it can be recognized as a viable and indispensable clinical modality. Several clinical longitudinal studies justify this observation.⁸⁻¹⁰ The esthetic quality of the removable partial denture restoring missing anterior teeth can be improved to match that of its fixed counterpart.

It is the goal of this article to describe a simple method of improving the esthetic quality of removable partial dentures restoring partially edentulous patients with missing anterior teeth.

Materials and Methods

The primary and final impressions are carried out following the standard clinical procedure. Artificial teeth are selected according to the shade, form, and size that harmonize with the patient. After obtaining the master cast, jaw relation records are made and the upper and lower casts are mounted on an articulator. The ridge laps of the anterior teeth are custom ground to facilitate the arrangement of the teeth in a proper positional relationship without a labial flange [Fig.2]. After satisfying the best esthetic results with the anterior set-up, the labial surface of the teeth is lightly lubricated with vaseline. A plaster index is poured on the labial surface of the artificial teeth as well as on the labial surface of the adjoining stone teeth on each side. After the plaster sets, the index is separated from the cast and the excess that flowed beyond the teeth is trimmed off. The wax remnants attached to the artificial teeth and to the cast are flushed using boiling water. The plaster index is reset while the artificial teeth are in position on the cast [Fig. 3]. With a pencil, the outline of the metal extension (struts) that will project to fit into the lingual surface of the individual anterior teeth is drawn. The artificial anterior teeth are removed and hollowed out following the drawn outline; one should be careful not to thin-out the teeth labio-lingually in order to guard against showing the

metal struts through the labial surface. The lingual surface of the anterior teeth is lightly lubricated with vaseline. After obtaining the working cast and during the waxing-up of the partial denture framework, the plaster index and the modified artificial anterior teeth are repositioned on the cast carefully. Wax is flowed into the lingual depressions (created for the struts) of the anterior teeth. The rest of the framework is waxed-up in the conventional manner [Fig. 4] and then the plaster index and the modified teeth are gently removed and put aside [Fig. 5].

Spruing, investing, burn-out, casting and sandblasting the partial denture framework are done in the usual manner. The metal struts that project into the lingual surface of the anterior teeth are sliced into several sections with a thin disc in order to improve the retention or bonding of the tooth coloured acrylic resin. The framework is then finished and polished [Fig. 6]. After careful inspection of the fit and occlusion of the metal framework in the patient's mouth, recording of the maxillo-mandibular relation is done then transferred to the articulator.

Finally, the plaster index and the modified anterior teeth are repositioned into their respective places on the master cast, and the teeth are set by flowing base plate wax into the lingual surfaces of the anterior teeth and around the metal struts. Missing posterior teeth are arranged as well and waxed in position. The waxed-up denture is tried in the patient's mouth for esthetics, phonetics, and occlusion.

The trial denture is flaked, wax is eliminated, separating medium is applied, and heat-cured acrylic resin is packed in the area of the denture

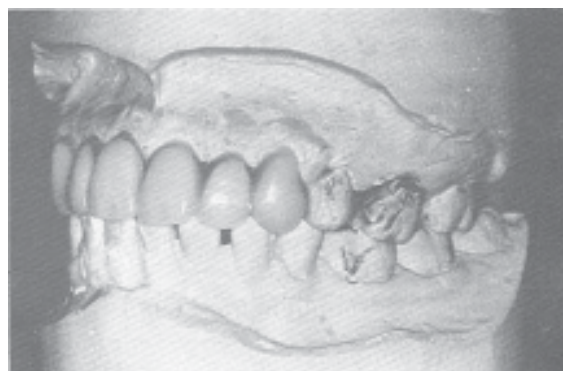


Figure 2. Artificial teeth set to satisfy the best esthetics and occlusion of the patient.

base. Tooth-coloured acrylic resin of suitable shade is also packed into the lingual surface of the modified anterior teeth. The removable partial denture is processed, finished and polished and then inserted in the patient's mouth [Fig. 8].

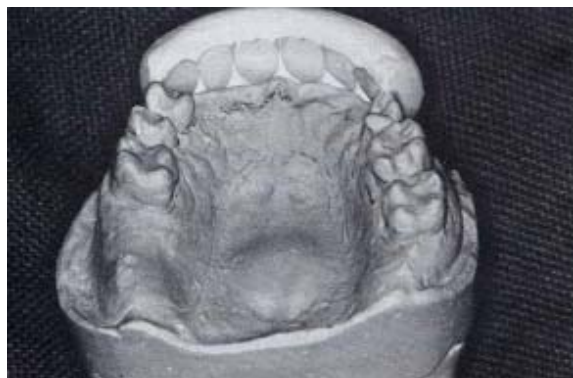

Figure 3. The plaster index is reset while the artificial teeth are in position on the cast.

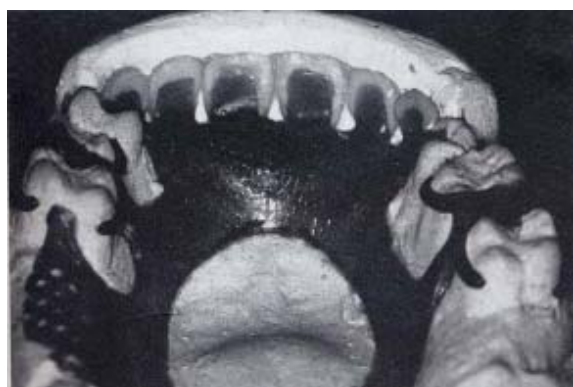

Figure 4. The plaster index and the modified anterior teeth are repositioned and waxing up of the RPD framework is performed.

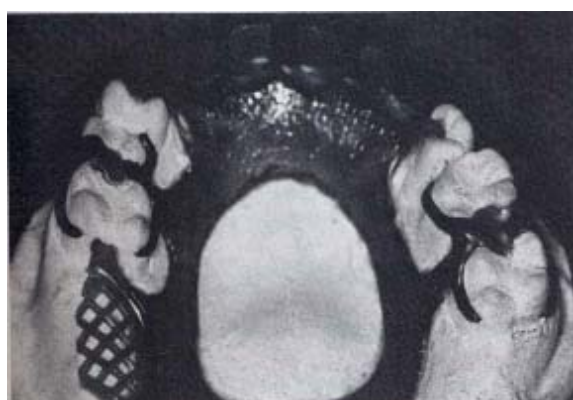

Figure 5. The finished removable partial denture wax up after removal of the plaster index and the modified anterior teeth.

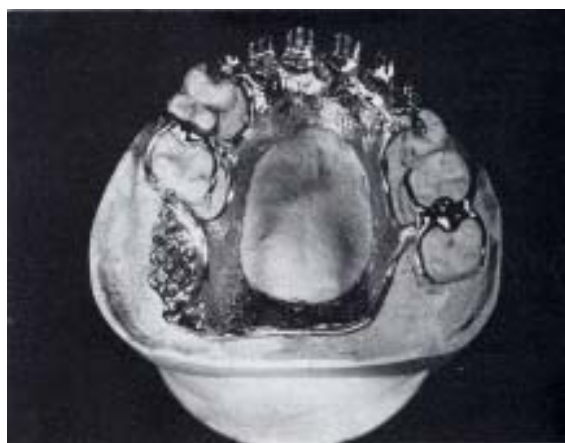

Figure 6. The polished partial denture framework on the master cast showing the slicing of the metal struts that will fit into the lingual surface of the modified anterior teeth.

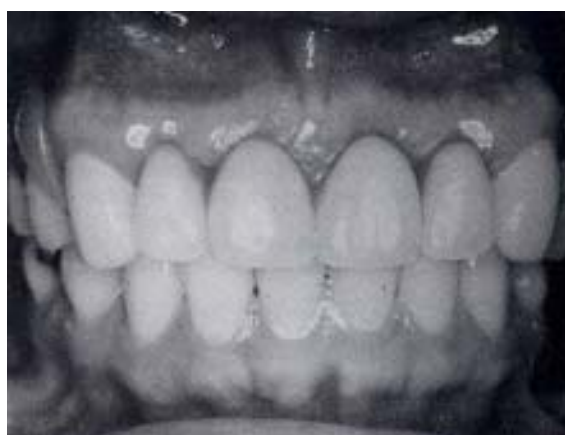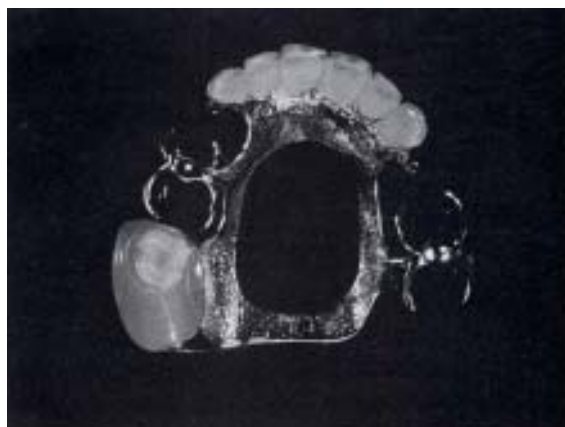


Figure 7. The finished removable partial denture. Fig. 8. Frontal view of a patient wearing the removable partial denture showing excellent esthetics.

Conclusion

The technique presented fulfills the basic removable partial denture design principles. It allows the dentist and the technician to evaluate, modify, and improve the esthetic arrangement of the anterior teeth in a removable partial denture very early in the course of treatment. Once the position of the anterior teeth is established, the partial denture framework is waxed-up accordingly, thus ensuring a strong attachment of the anterior teeth, avoiding gross recontouring of the artificial teeth to fit the existing removable partial denture framework and minimizing metal display. A high quality esthetic result was achieved using the above technique.

References

1. Smith B. Esthetic factors in removable partial prosthodontics. *Dent Clin North Am* 1979;23(1) : 53-63.
2. Zarb GA, Mackay HF. Cosmetics and removable partial dentures. The Class IV partially edentulous patient. *J Prosthet Dent* 1981 ;46(4):360-8.
3. Schwartz NL, Whitseh LD, Berry TG, Stewart JL. Unserviceable crowns and fixed partial dentures: Life-span and cause for loss of serviceability. *J Am Dent Assoc* 1970;81:1395.
4. Zarb GA, Bergman B, Payton JA, Mackay HF. *Prosthodontic treatment for partially edentulous patients*. St. Louis: CV Mosby Co, 1978.
5. Axelsson P, Lindhe J. The effect of a preventive programme on dental plaque, gingivitis, and caries in school children. Results after one and two years. *J Clin Periodontol* 197;4(2):126-38.
6. Lindhe J, Hamp S, Loe H. Experimental periodontitis in beagle dog. *J Periodont Res* 1973;803:1-10.
7. Loe H, Theilade E, Jensen SB. Experimental gingivitis in man. *J Periodontal* 1965;36:177.
8. Bergman B, Hugoson A, Olsson CO. Caries and periodontal status in patients fitted with removable partial dentures. *J Clin Periodontol* 1977;4(2):134-46.
9. Derry, A. and Bertram, U.: A clinical survey of removable partial dentures after 2 years usage. *Acta Odontol Scand* 1970;28(5):581-98.
10. Bertram U. A clinical survey of removable partial dentures after 10-year usage. *IADR 1979;Abstr No. 234*.