

## B-clasp: A new retentive component of removable appliance and its clinical application

Mohammed T. Bukhary, BDS, D. OrthoRCS, M. OrthoRCS (Edin)  
M. OrthoRCS (Lond), MDORCPS (Glasg), PhD (Lond)

هدف هذا البحث هو تقديم نوع جديد من الضامات المثبتة (ضمة - ب) للأجهزة المتحركة والتي تنتسبث إلى سطح أنبوب أطواق الرحي في الأجهزة الثابتة. ضمة - (ب) عبارة عن لولب ثنائي تصنع من اسلاك الصلب مقاس 0,7 مم وتتكون من لولب امامي و جسر ولولب خلفي وعابر وطرف معدني. تم عرض طريقة التحضير والاستخدامات السريرية. وقد ثبت أن ضمة - ب عملية وفعالة ومثبتة في العديد من استخدامات السريرية في تقويم الأسنان .

The objective of this paper was to introduce a new type of retentive clasp (B-Clasp) for the removable appliance that engages the roof of the molar tube in the fixed appliance. It is a bi-helix clasp made from 0.7 mm stainless steel wire and consists of mesial helix, bridge, distal helix, flyover and tag. Its fabrication and clinical applications are presented. Clinically, the B-clasp proved to be practical, effective and retentive in several clinical applications in orthodontics.

### INTRODUCTION

Fixed orthodontic appliances are the appliance of choice for the comprehensive orthodontic treatment.<sup>1</sup> They are capable of multiple teeth movements including bodily, torque and rotational movements.<sup>2</sup> Removable appliances, that were very popular at one time<sup>3</sup>, are capable only of simple tipping movements.<sup>4</sup> They are no longer the appliance of choice for the treatment of malocclusion.<sup>1,2,5</sup> Their contemporary use includes specific intervention in the mixed dentition and as an adjunct to fixed appliances.<sup>1-5</sup> Therefore, it will be of great clinical advantage to combine both appliances in the treatment of malocclusion. The flat occlusal biteplane of the removable appliances can free occlusal interferences of the teeth in cross bite.<sup>6</sup> This allows the early correction of cross bite and alignment of teeth by the fixed appliances.<sup>6-8</sup> However, the attachment of the different components of the fixed appliances to the teeth surfaces does not allow the use of removable appliances at the same time. When the molar bands are cemented to the first molars, it becomes impossible to use Adam's clasp.<sup>6-8</sup> The use of alternative clasps, C-clasp or ball-

end clasp was impractical.<sup>7</sup> Therefore, the introduction of a new type of clasp for the removable appliance is necessary to combine the use of removable and fixed appliances during orthodontic treatment.

Foster<sup>7</sup> described a clasp for the removable appliance that fits over the molar band of the fixed appliance. The clasp "modified retention loop" is a modification of the C-clasp with a loop bended over the tube of the molar bands. Jones and Oliver<sup>8</sup> described a similar clasp that fits over the molar bands. The clasp described is rigid, difficult to fit and remove, and easily distorted. Bank and Carmichael<sup>9</sup> introduced a single arrowhead clasp for the retention of removable appliance that engages the undercut between two anterior teeth and fit under the archwire of the fixed appliance. The clasp is difficult to construct and require aligned anterior teeth with no spaces. This made it difficult to use in the early stage of the fixed appliance treatment. In addition, it created spaces between the anterior teeth, caused rotation of teeth and could cause apical displacement and damages to the gingival tissue. Bank and Carmichael<sup>9</sup> modified the arrowhead clasp to avoid the

Received 24 December 2005; Accepted 22 April 2006  
Associate Professor and Consultant  
Department of Preventive Dental Sciences  
College of Dentistry, King Saud University

Address reprint requests to:  
Dr. Mohammed T. Bukhary  
College of Dentistry, King Saud University  
P.O. Box 60169, Riyadh 11545, Saudi Arabia  
Email: mtbukhary@hotmail.com

problems with the previous design. The new modification had similar problems.

The objective of this paper was to introduce a new retentive clasp (B-clasp) for the removable appliance that is of great clinical advantage to combine with the fixed appliance.

## MATERIALS AND METHODS

The B-clasp is a bi-helix clasp constructed from 0.7 mm spring hard stainless steel wire. It consists of mesial helix, bridge, distal helix, flyover and tag (Fig. 1). It engages the roof of the molar tube of the upper molar band of the fixed appliance from the distal aspect (Figs. 2a and 2b).

### MATERIALS

The materials needed for the construction of the B-clasp and the base plate that can fit over the molar bands were as follows:

1. upper working model with the imprint of the molar tube of the bands
2. 0.7 mm stainless steel spring hard wire
3. bird beak plier
4. wire cutter
5. cold cure acrylic
6. separating medium
7. wax knife
8. wire marker

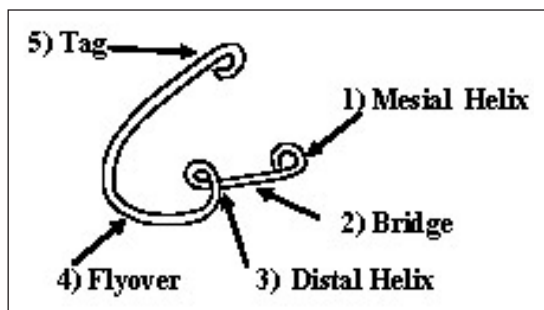


Fig. 1. Component of the B-clasp.

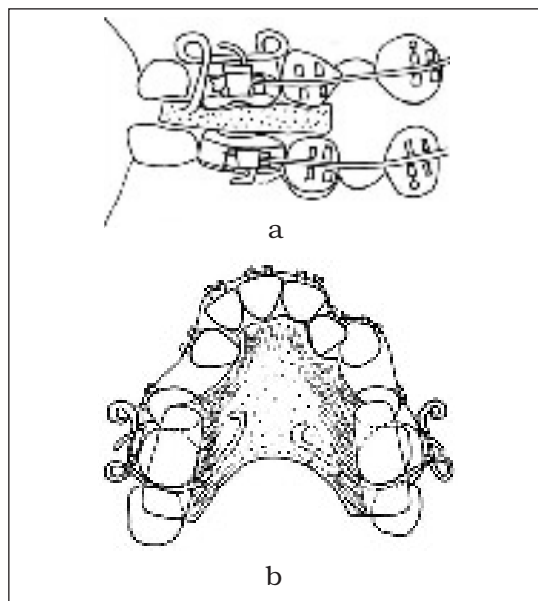


Fig. 2 (a and b). Illustration of the engagement of B-clasp to the molar bands.

### METHOD

The following steps are used for the construction of the B-clasp and the base plate:

#### Model Preparation

The working model was prepared from alginate impression with the molar bands fitted on the patient molar teeth (Fig. 3a). The stone above the roof of the molar tubes and hooks was removed with a round bur or wax knife. The roof of the molar tubes is a free area of huge undercut that was utilized by the bridge of the B-clasp for the retention of the removable appliance (Figs. 3b and 3c).

B-Clasp Construction was done in the following reference:

1. Cutting about 8 cm long 0.7 mm stainless steel wire.
2. Bending the mesial helix at the tip of the wire (3mm in diameter) by the bird beak plier (Fig. 4a).




Fig. 3 (a, b and c). The model preparation.

3. Putting the wire at the roof of the molar tube with the mesial helix extending about 3 mm mesial to the molar tube and mark the length of the bridge of the clasp (Fig. 4b).
4. Bending the distal helix about 3 mm in diameter at the location of the mark (Fig. 4c).
5. Bending the flyover passing over the bridge and extending above the contact point of the molar (Fig. 4d).
6. Extending the tag over the palatal surface, ending in a semi circle or turn-in bend which was embedded in the acrylic (Fig. 4e).
7. Repeating the same procedure for the molar band of the other side.

### Base Plate Construction

The base plate was made of cold cure acrylic and prepared according to the manufacturer's instructions. It is the supportive component of the appliance. It contained the bite plane (anterior or posterior) and held the B-clasp. The procedures of the baseplate construction were sequentially as follows:

- 1) Fitting the B-clasp on both sides and fix it in place with a sticky wax (Fig. 5a).
- 2) Applying the separating medium on the model.
- 3) Applying the cold cure acrylic and make a flat bite plane (posterior or anterior).

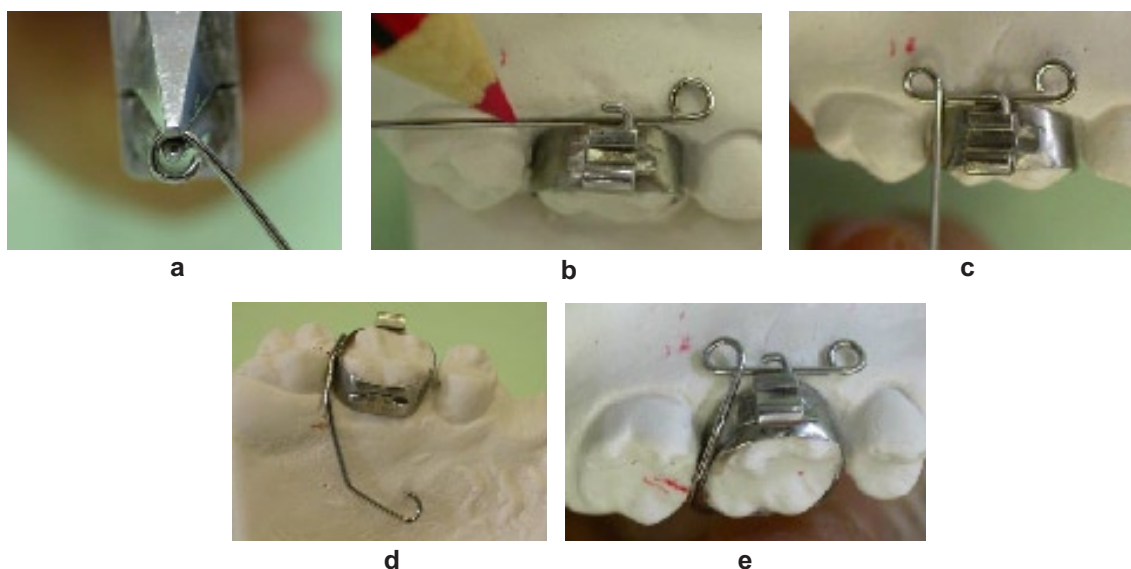


Fig. 4 (a, b, c, d, and e). B-clasp construction.

- 4) Allowing the cold cure acrylic to set under pressure.
- 5) Making the mesial helix bent about 45 degrees to the bridge (Fig. 5b and 5c).
- 6) Cleaning and polish (Fig. 5d).

#### Guidelines in the Construction

1. The B-clasp should engage the roof of the upper molar tube.
2. The out bend of the mesial circle should simplify the fitting and removal of the appliance.
3. The distal circle should follow the contour of the buccal gingival morphology and not press against the gingiva.
4. The flyover should start above the bridge and should not block the distal orifices of the molar tube or interfere with the arch wire.


5. The bite planes should cover the occlusal table of the upper molars with enough occlusal clearance.
6. The leveled anterior bite plane with the upper incisor edges should be wide enough to engage the lower incisors.

#### Clinical Application of the B-Clasp

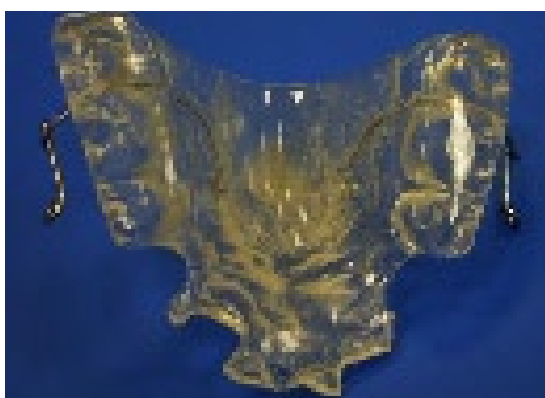The constructed removable appliance with the described B-clasp fitted over the molar bands was used in conjunction with the fixed appliance. The following widely different clinical cases were treated utilizing the B-clasp as a retentive component in combination with fixed appliance.



a



b



c



d

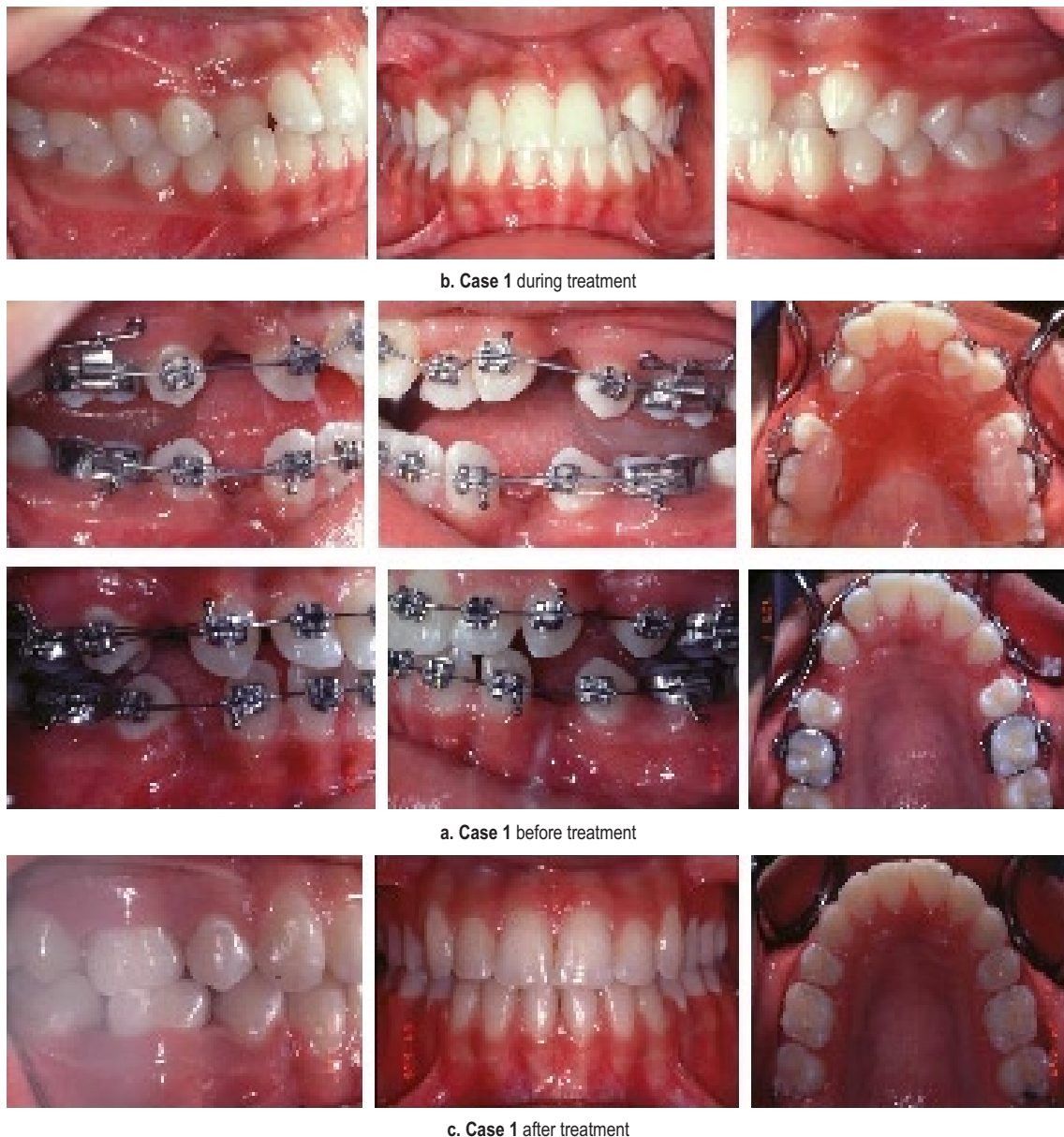Fig. 5 (a, b, c and d). Base plate construction.

**Case 1**

Class I malocclusion case. A bi-maxillary dental protrusion with crossbite in the upper right canine and upper left lateral incisor.

An upper removable appliance retained with B-clasps (over the molar tube of the

upper molar band) and with a posterior bite plane to eliminate the occlusal interference was used together with fixed appliance to correct crossbite and align the malpositioned upper right canine and upper left lateral incisor (Fig. 6).



**Fig. 6 (a, b, and c).** Case I before, during and after treatment of anterior cross bite by the fixed appliance, posterior bite plane and B-clasp.

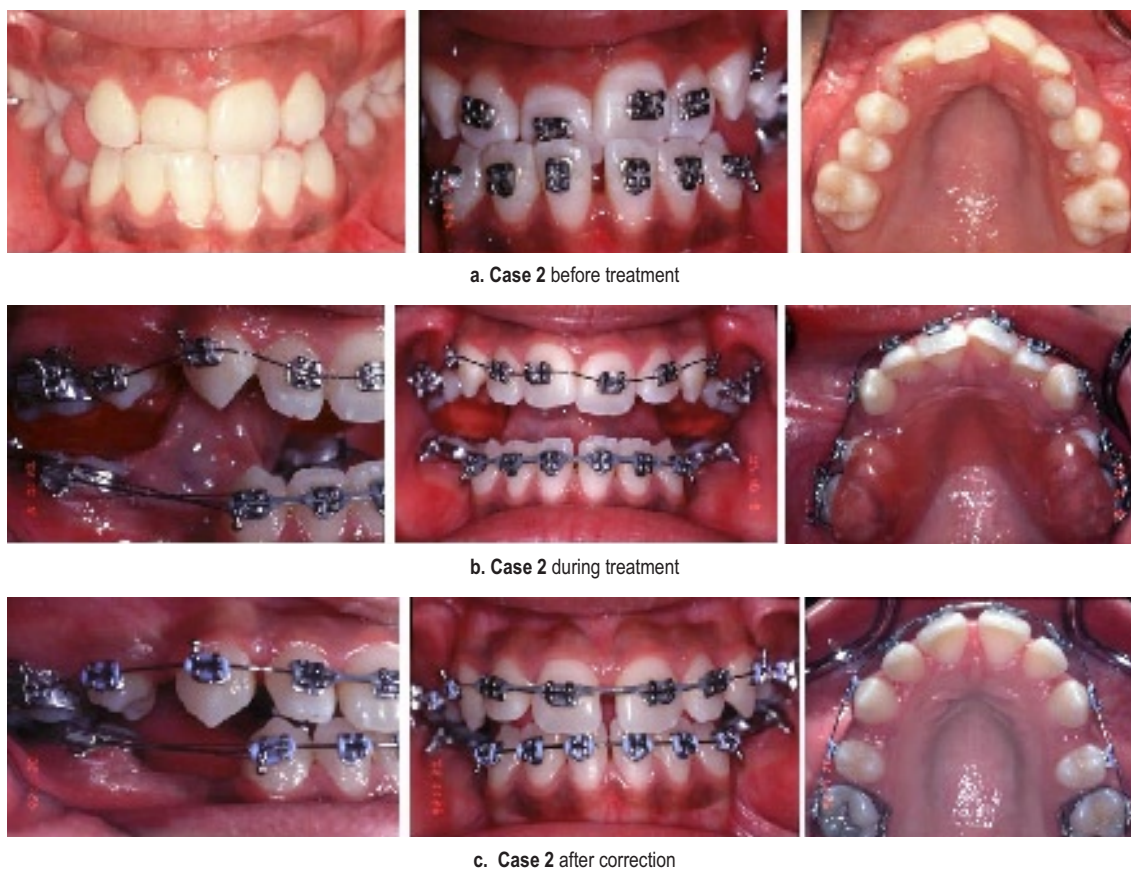


Fig. 7 (a, b, and c). Case 2 before, during and after treatment of anterior cross bite by the fixed appliance, posterior bite plane and B-clasp.

### Case 2

Class III malocclusion case with the upper anterior teeth in crossbite. The case was treated with fixed appliance in conjunction with a removable appliance. An upper removable appliance retained with the B-clasp and posterior bite plane to disengage the bite was used to correct the anterior crossbite (Fig. 7).

### Case 3

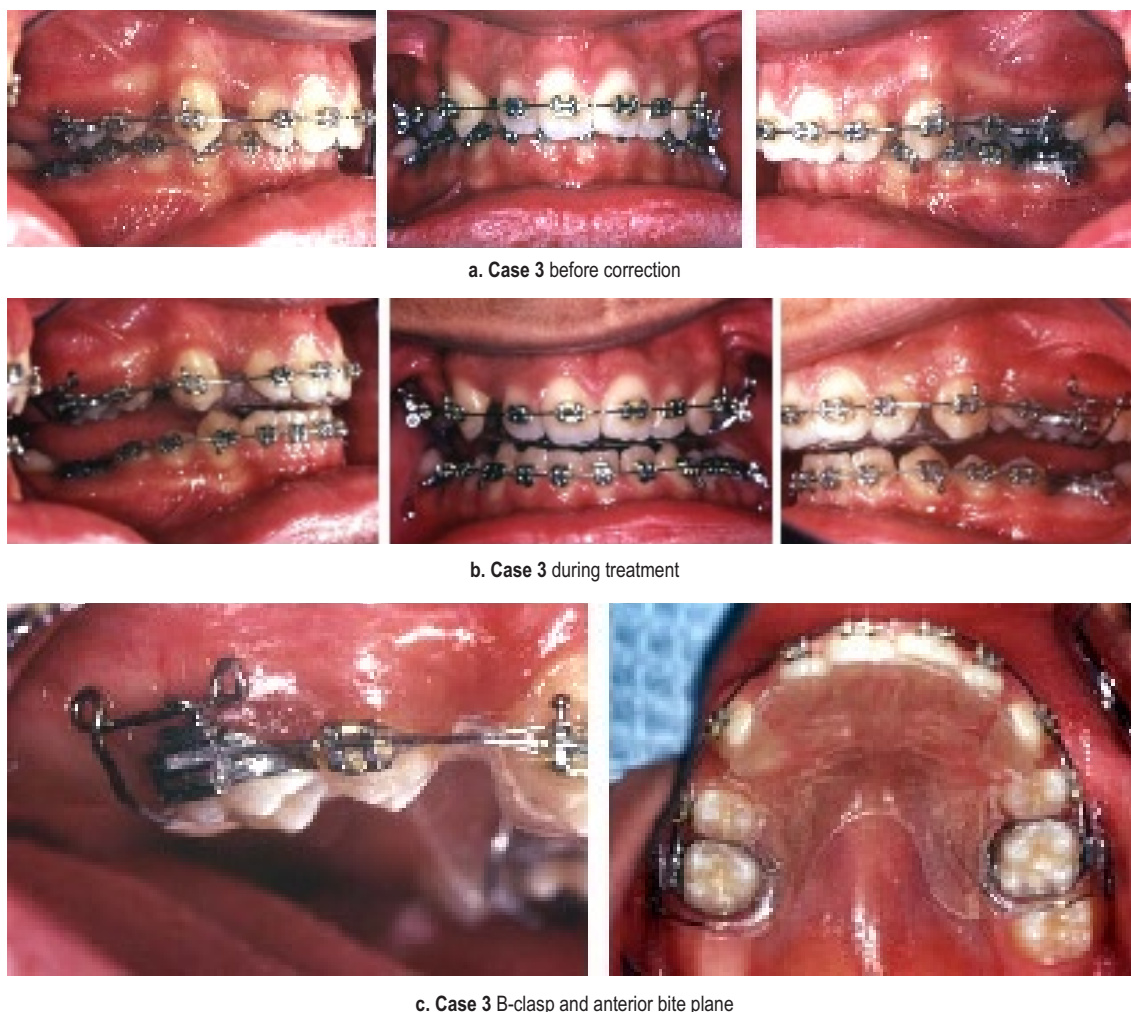Class II malocclusion case with severe deep anterior overbite. The case was treated with fixed appliance in combination with an upper removable appliance. The removable appliance with the anterior bite plane was retained by

B-clasp fitted over the molar bands to reduce the deep overbite (Fig. 8).

### Case 4

A class I malocclusion patient. He was in the mixed dentition stage. He had a history of fractured upper right central incisor due to an accident. The referring dentist requested the extrusion of the remaining part of the fractured upper central incisor in order to perform root canal treatment and build it up temporary.

The patient was treated with an upper removable appliance retained by B-clasp and web design spring. The web design spring was fabricated to extrude the fractured tooth. The fractured crown



a. Case 3 before correction

b. Case 3 during treatment

c. Case 3 B-clasp and anterior bite plane

Fig. 8 (a, b, and c). Case 3 before and during treatment of deep over bite by the fixed appliance, anterior bite plane and B-clasp.

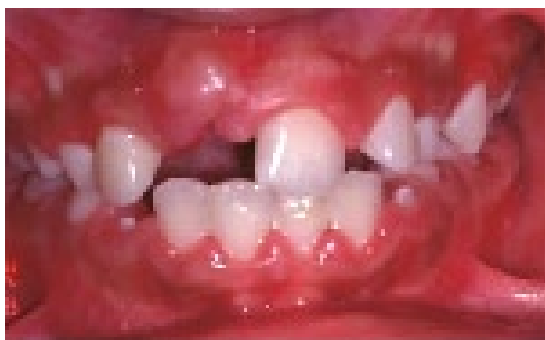was surgically exposed and a bracket was bonded to the fractured crown. The activated web design spring extruded the tooth within a short period of time and a root canal treatment was performed (Fig. 9).

### DISCUSSION

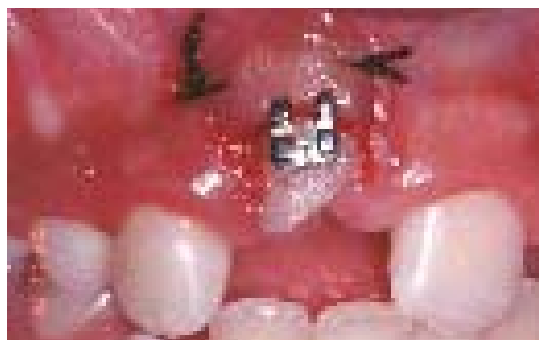
The demand for orthodontic treatment continues to increase rapidly. Contemporary treatments are mostly carried out by fixed orthodontic appliances. However, the removable appliances were part of orthodontics

treatment and have recently become a useful adjunct to the fixed appliance therapy.<sup>1-6</sup> This is in contradiction to the view of Mew<sup>10</sup> who stated that the removable appliance has no place in contemporary orthodontic.

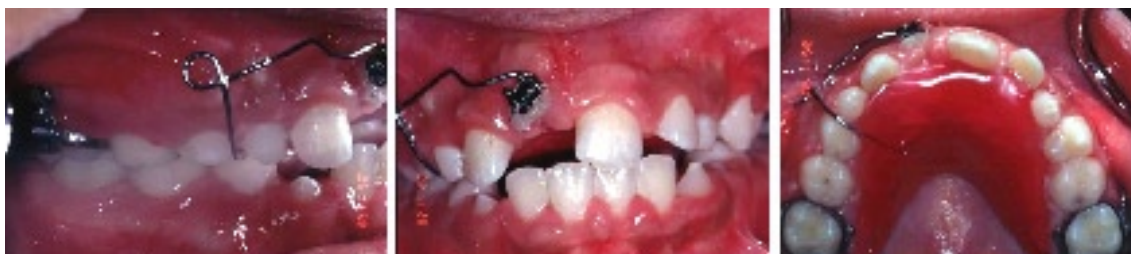The present study introduces a new design of clasp (B-clasp) that allows the use of a removable appliance in conjunction with the fixed appliance. During the fixed appliance treatment, the presence of the removable appliance with a bite plane helped in the correction of teeth in cross bite and in the reduction of deep



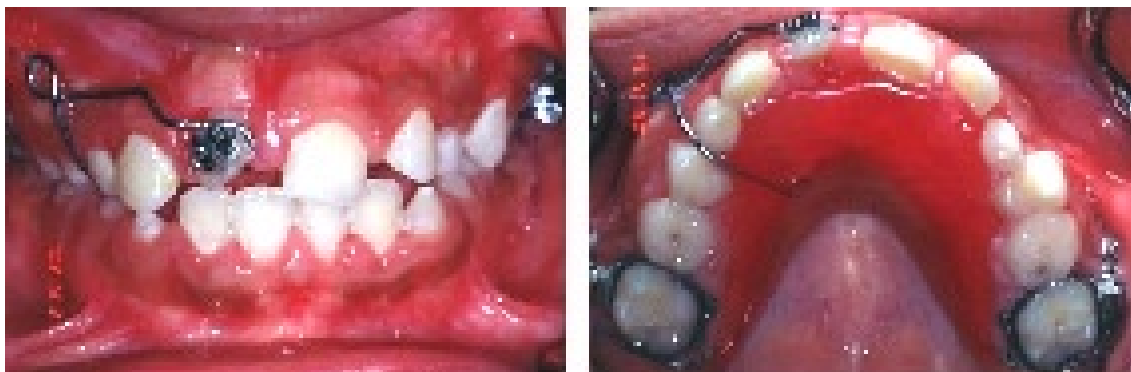a. Case 4 before treatment



b. Case 4 surgical exposure and bracket bonding



c. Case 4 during treatment



d. Case 4 before endodontic treatment

**Fig. 9 (a, b, c and d).** Case 4 before, during and after treatment of fractured upper incisors by web design spring and B-clasp over upper first molar bands.

overbite. The anterior bite plane helped in bonding of brackets in the lower incisors in cases with severe deep bite cases.

When compared with other types of clasps,<sup>6-9</sup> the B-clasp is simple to construct, easy to adjust, easy to fit, remove, very retentive and not expensive. The main advantage of B-clasp is that it combines the use of removable and fixed appliances without any interference with

the treatment mechanics. It engages the roof of the molar tube from the distal aspect with no contact with any components of the fixed appliance. The single arrowhead clasp designed by Bank and Carmichael<sup>9</sup> engages the undercut between the central and lateral incisors. The clasp passes between the brackets of the central and lateral incisors under the archwire of the fixed appliance. This may

interfere with the treatment by contacting the archwire. The helix of the B-clasp makes it flexible for easy insertion and removal of the appliance. In contrast, the modified retention loop of Foster<sup>7</sup> and Jones *et al.*<sup>8</sup> is rigid and distorts easily during insertion and removal of the appliance. The B-clasp is very retentive because it engages a very wide area of undercut over the roof of the molar tube. In addition, the hook of the molar tube will act as a posted barrier to prevent side dislodgment of the clasp.

The orthodontist will find the B-clasp helpful in several clinical situations that need correction and alignment of teeth in cross bite (Cases 1 and 2), reduction of deep bite cases and facilitation of bracket bonding of lower incisors in deep bite cases when there is a need to bond them from the beginning of the treatment (Case 3). Further, it is of great help in high angle cases that need upper arch expansion and prevention of molar extrusion by the addition of posterior bite plane and also in cases that needs extrusion of fractured teeth (Case 4). Furthermore, it also serves as a space maintainer and carries artificial teeth in cases of missing incisors for esthetic reasons.

The removable appliance retained with the B-clasp used in combination with fixed appliance is of great help to the orthodontist in the management of different clinical orthodontic situations.

### CONCLUSION

The removable appliance retained with B-clasp is very retentive, simple and easy to construct. It is very easy to fit and remove. Moreover, it is not expensive. Hence, the B-clasp has a great clinical advantage when combined with fixed appliances in orthodontic treatments.

### ACKNOWLEDGEMENT

The author is thankful to Prof. N. Babay for reading the manuscript and to all those who participated to produce this study.

### REFERENCES

1. Ward S, Read MJF. The contemporary use of removable orthodontic appliances. *Dent Update* 2004; 31: 215-218.
2. Littlewood SJ, Tait AG, Mandall NA, Lewis DH. The role of removable appliances in contemporary orthodontics. *Br Dent J* 2001; 191:304-310.
3. Kerr WJS, McColl JH, Frostick L. The use of removable orthodontic appliances in the general dental service. *Br Dent J* 1996; 181:27-32.
4. Hoyle A. The development of removable appliances in the United Kingdom. *Br J Orthod* 1983; 10: 73-77.
5. Turner PJ. Use of removable appliances as an adjunct to fixed appliance therapy. *Dent Update* 1993; 20: 428-432
6. Adams CP, Kerr WJS. The design and use of removable orthodontic appliances, 6<sup>th</sup> edition. Oxford: Butterworth-Heinemann, 1990.
7. Foster TD. Textbook Introduction to Orthodontics, 3<sup>rd</sup> edition. Oxford: Blackwell Scientific Publication, 1990.
8. Jones ML, Oliver RG. Walther and Houston's orthodontic notes, 5<sup>th</sup> edition. Oxford: Butterworth-Heinemann, 1997; 163-167.
9. Banks PA, Carmichael G. Modified arrowhead clasps for removable biteplanes. *J Clin Orthod* 1998; 6:377-378.
10. Mew J. The removable appliance has no place in contemporary orthodontic treatment and the evidence for this statement is overwhelming. *Br J Orthod* 1998; 25: 235.