

## FABRICATION OF A COMPLETE DENTURE IN ONE-VISIT USING TRIAD VISIBLE LIGHT CURED (VLC) RESIN - A CASE REPORT

Mansour K. Assery, BDS, MS\* and Saleh M. Al-Shamrani, BDS, MS\*\*

في بعض الحالات بسبب ضيق الوقت أو نقص في المواد فإن أخصائي التعويضات يمكنه أحياناً الاستفادة من بعض الطرق المعدلة لانجاز المعالجة.

تم تطوير الراتنج المتصلب بالضوء المرئي لاستخدامه في مختلف مجالات التعويضات السنية. وبمواصفات مماثلة لمواصفات الصفائح القاعدية المتصلبة بالحرارة.

وإن الراتنج المتصلب بالضوء المرئي متوفر الآن في الأسواق بثخانة الصفائح القاعدية وبشكل حبال راتنجية. وهذا الراتنج شبيه بالمواد الحاشية التي تتصلب بالضوء.

الهدف من هذا البحث. وصف الطرق السريرية والمخبرية لعمل صفيحة علوية كاملة بجلسة واحدة باستخدام الراتنج المتصلب بالضوء المرئي.

مريض عمره ٦٥ سنة حول إلى عيادة التعويضات في مستشفى القوات المسلحة بالطائف لعمل صفيحة علوية كاملة. حيث لدى المريض صفيحة سفلية كاملة بحالة جيدة. وقد فقد فقط الصفيحة العلوية. المريض يعمل استاذاً ومن المهم جداً ان يكون لديه صفيحة علوية بأسرع وقت ممكن.

تم صنع صفيحة علوية له من مادة الراتنج المتصلب بالضوء المرئي بجلسة واحدة. ووضعت الحالة تحت المراقبة للتأكد من الالتحام الكيميائي والفيزيائي وعدم انفصال الأسنان الاكبرلية عن المادة الراتنجية. وبعد مضي سبعة أشهر على المراقبة لم يحدث أن انفصال. ومن المتوقع أن يدوم الالتحام بقدر ما هو عليه في الصفائح المصنوعة من الراتنج المعتاد.

على أي حال حتى لو لم يدم الالتحام كما هو عليه في الصفائح المصنوعة من الراتنج المعتاد، يبدو أن لهذه المادة مكان لاستخدامها في هذا المجال نظراً لسهولة وسرعة استعمالها وتوفيرها للوقت.

In this case report, a method for fabricating a complete denture in one-visit using Triad Visible Light Cured (VLC) resin is described.

### Introduction

Under circumstances related to shortage of materials or limitation of time, it can be helpful for the prosthodontist to utilize alternative procedure to expedite treatment.

Received 20/07/94; revised 14/11/94; accepted 19/02/95.

\*Chief of Dental Department, Al Hada Armed Forces Hospital, P.O. Box 1347, Taif, Saudi Arabia.

\*\*Assistant Professor, Department of Restorative Dental Sciences, and Director of Clinics (DUC), King Saud University, College of Dentistry, P.O. Box 60169, Riyadh 11545, Saudi Arabia.

Address reprint requests: Dr. M.K.Assery

Triad Visible Light-Cured (VLC) resin<sup>1</sup> has been developed for many prosthodontic applications<sup>15</sup> and has met the requirements for heat-cured base materials (American Dental Association specification No. 12). This VLC resin is available from dental suppliers in sheets of base plate thickness and in rope-form in light sealed envelopes. This VLC is similar to light-cured filling materials. The matrix is urethane dimethacrylate with enough microfine silica to provide workable handling qualities. There is no free methyl (methacrylate) monomer in the uncured or cured material.

<sup>1</sup>Triad (R), Dentsply International, York, PA, USA.

The purpose of this paper is to report the clinical and laboratory procedures to fabricate an upper complete denture in one-visit using VLC resin.

#### Technique

A 65-year-old edentulous male was referred to the Prosthodontics Clinic at Al-Hada Armed Forces Hospital in Taif for construction of an upper complete denture. The patient has a lower complete denture in good condition but the upper denture was lost. Being a teacher, it was important for him to have a denture as soon as possible.

An upper alginate impression was taken using a metal tray. The impression covered all the edentulous areas including the adjacent landmarks [Fig. 1a]. A study cast was prepared from the alginate impression and all the undercuts were blocked out with wax. A post dam area was prepared and then an air barrier coating was applied [Fig. 1b]. VLC resin sheets were adapted well to the prepared model making sure that no voids were created. It was cured in the Triad machine for 10 minutes according to the manufacturer's instructions. The material was then treated with air barrier coating and cured for 5 more minutes. An occlusal rim was constructed on the cured base to be used in recording jaw relation [Figs. 2a,b]. Vertical dimension of occlusion and centric relation records were obtained. Upper cast and lower denture were mounted on a hinge articulator [Figs. 3a,b]. Teeth of the proper mold and shade were selected. Retentive holes were prepared in the necks of the teeth. Bonding agent was applied and cured according to the manufacturer's instruction [Fig. 4a].

The occlusal rim was removed and replaced by a rope-form VLC resin. The teeth were arranged in the right position according to aesthetics and occlusion. The set-up, partially cured in the articulator, was tried and again cured in the patient's mouth [Figs. 4b and 5a]. New VLC resin was added to the border of the cured base and the maxillary denture was again border molded. The denture was sent to the laboratory for finishing and polishing. The denture was delivered to the patient [Fig. 5b].

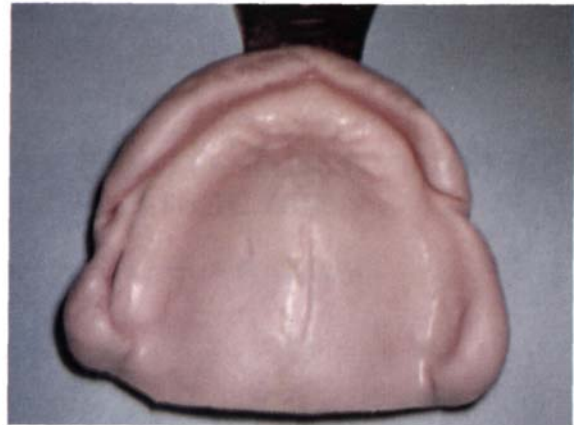

Figure 1a. An upper maxillary alginate impression.

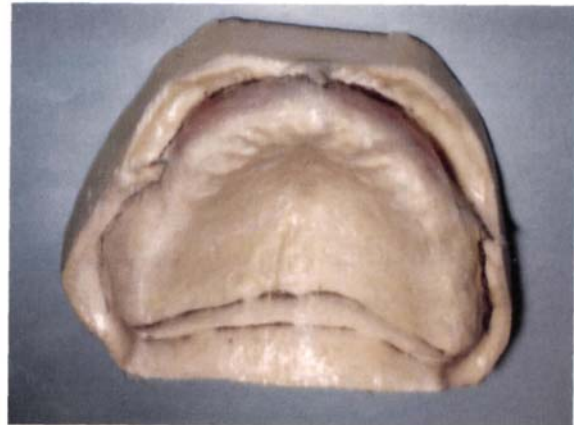

Figure 1b. A study model with prepared post dam.

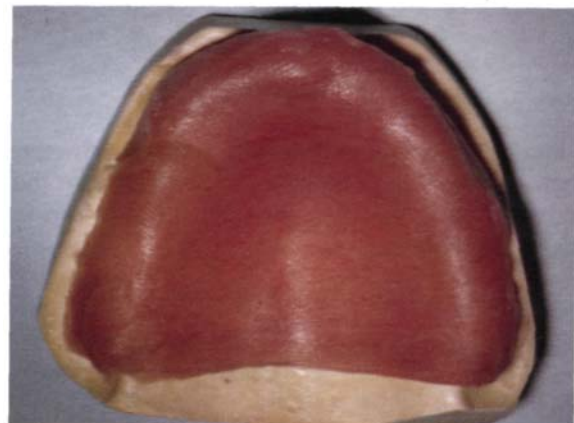

Figure 2a. VLC resin sheet adapted to the model.

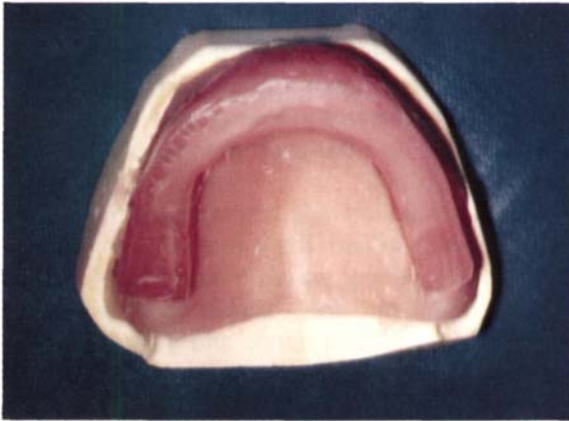


Figure 2b. Occlusal rim.

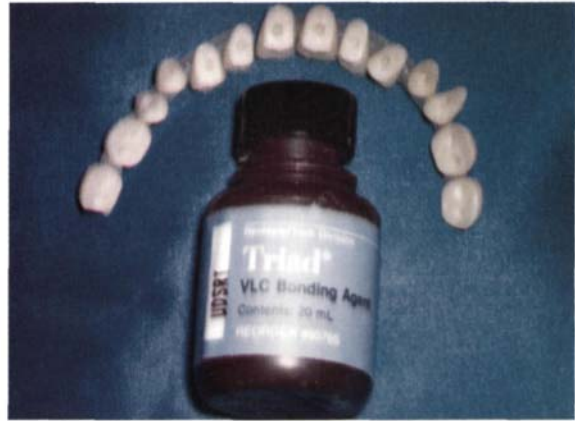

Figure 4a. Retentive holes in the teeth.

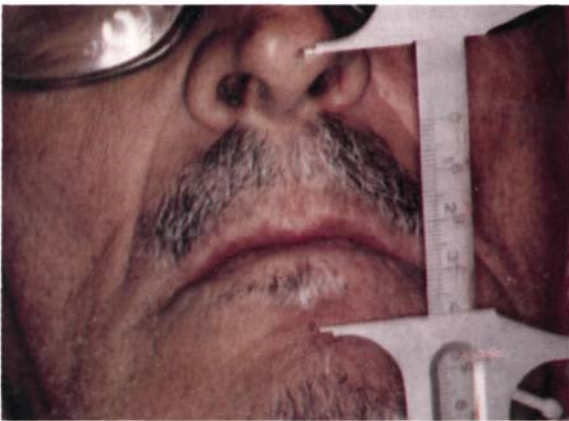


Figure 3a. Vertical dimension of occlusion.

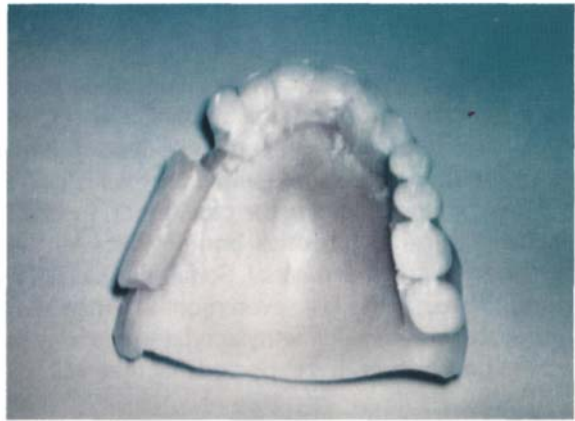


Figure 4b. Setting the teeth in the rope-form VLC resin.

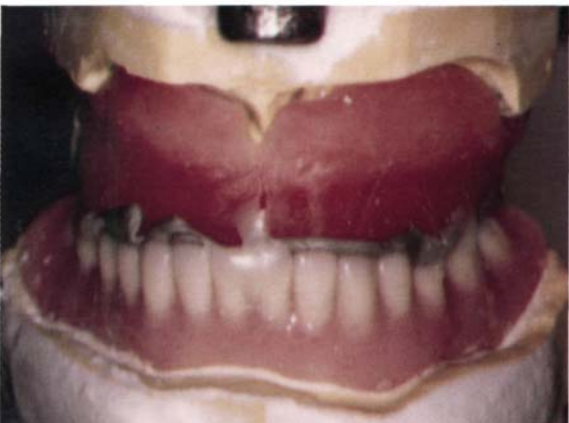

Figure 3b. Maxillary cast and mandibular denture mounted.

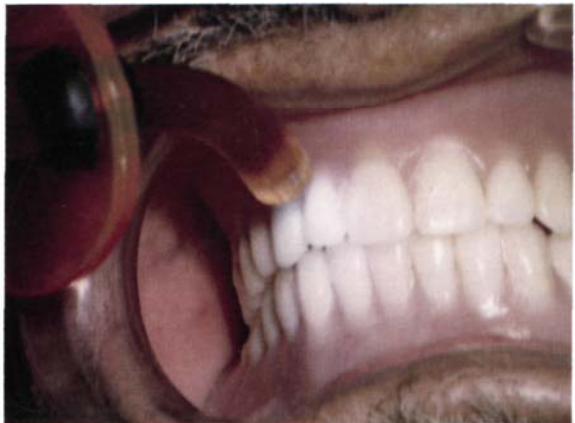

Figure 5a. VLC resin partially cured in the patient's mouth.

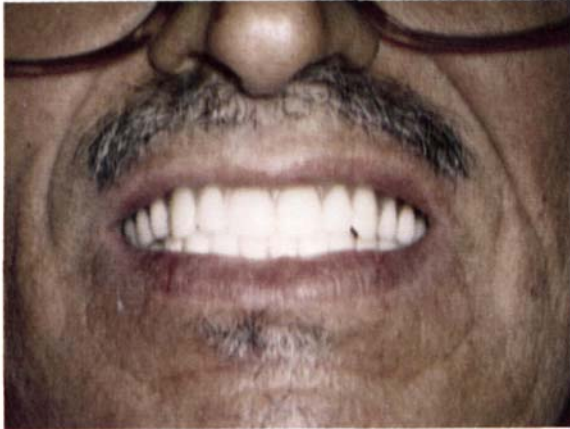

Figure 5b. Final results.

### Discussion

Visible light-cured resin has been developed and used for many prosthodontic applications. However, its use for one-visit complete denture construction has not been independently evaluated.

The worrisome point in the case under review is the mechanical and chemical bonding between the acrylic teeth and the material. So far, this has withstood the test in the last seven months. Since VLC resins are urethane dimethylacrylate matrix with acrylic co-polymer, it is expected that they will last

as long as conventional PMMA resins bond well with them. However, even if the bonding is relatively short-lived, there appears to be a place for the use of this material in view of its relative ease of manipulation and the short time involved in the method described.

The materials and method employed in this case study have satisfied the prosthetic emergency needs of this patient, so far. It therefore justifies its recommendation for similar prosthodontic emergencies. Further work and follow-up are, however, recommended.

### References

1. Ogle RE, Sorensen SE, Lewis EA. A new visible light-cured resin system applied to removable prosthodontics. *J Prosthet Dent* 1986;56:497-506.
2. Othman HR. Refitting denture base with a visible light cured denture base resin. *New York State Dent J* 1986;52:29-32.
3. Nimmo A. Correction of the posterior palatal seal by using visible light-cured resin: a clinical report. *J Prosthet Dent* 1988;59:529-31.
4. Tan HK, BrudvickJS, Nicholls JI, Smith DE. Adaptation of a visible light-cured dental base material. *J Prosthet Dent* 1989;61:326-31.
5. Assery MK, Al-Shamrani SM. Chairside denture relining with VLC resin: new material report. *Saudi Dent J* 1991;3:117-19.