

Case Report

RESIN-RETAINED FIXED-MOVEABLE BRIDGE DESIGN: CASE REPORT

BabatundeO. Olorunfemi, BDS, M.Med.Sci.*

الحالة التي سجلت توضح استخدام الحشوات المصبوبة كمثبتات للجسر الثابت المتحرك بعد استخدامها لمدة عامين والحالة لفتاة عمرها ثلاثون عام كانت قلقة جداً لمظهرها وقد حضرت إلى عيادة الأسنان لتركيب الضاحك الثاني العلوي الأيمن وبالفحص الأكلينيكي تبين أنه غير موجود مع وجود حشوات كمبوزيت على الضاحك الأول العلوي الأيمن والرحى الأولى اليمنى والناحية الصحية العامة للمريضة جيدة كذلك باقي الأسنان.

العلاج:

يتضمن استعمال الحشوات المصبوبة المغطاة بالخزف كمثبتات للجسر الثابت المتحرك مع عمل التعديلات اللازمة لشكل السن وقد تم تثبيت الجسر اللاصق باستخدام (ميراج ف. ال. سي) وهذه المادة ذات نظام ثنائي التصلب وبعد تثبيت الجسر مباشرة تكونت في الأسنان حساسية اختفت بدورها بعد سنة وقد أوضحت الدراسة بأن الحشوات المصبوبة الملتصقة يمكن أن تعتبر مثبتات اختبارية في التعويضات الثابتة.

This case is a report on the management of a missing upper second premolar in a highly aesthetically motivated female patient using a fixed moveable bridge design with mesial and distal retainers for two years. The bridge was made from non-precious metal substructure and porcelain backing, using current composite resin in an adhesive technique. Postoperatively, the patient complained of tooth sensitivity which eventually disappeared after one year.

Introduction

A 30-year-old Afro-Caribbean female serving as an industrial cycling officer reported in the clinic requesting a fixed denture replacement for her missing upper right second premolar. The medical history was not contributory. She had both dental extraction and fillings done previously.

Case Report

Clinical Examination

Extraorally, she presented as a healthy looking young lady with no abnormality in her facial profile. Intraorally, all her teeth were present from the central incisor to the third molar in all quadrants excluding the missing upper right second premolar. There was a composite resin disto-occlusal filling on tooth # 14 and a mesio-occlusal filling on tooth # 16. The oral mucosa was healthy and oral hygiene was good. She had a canine-guided occlu-

sion. Radiographic examination confirmed the presence of satisfactory composite resin restorations on teeth # 14 and # 16 and occlusal amalgam fillings on teeth # 36 and # 37. A diagnosis of partial edentulousness due to a previous extraction of the upper right second premolar was made. The prognosis of treatment was considered as good.

Treatment Regime

It was decided that a ceramic-resin bonded posterior bridge be constructed for the case. Composite resin restorations on teeth # 14 and # 16 were removed and the cavities were modified so that these teeth could be used as inlay abutments. Undercuts were blocked with a Ketac-fil* glass ionomer cement. An impression of the upper jaw was taken by using Provilt curing silicone impression material. Alginate was used for taking the articulating impression of the lower jaw. Vita shade D2t was selected as the tooth shade for the bridge.

The fixed-moveable bridge design was chosen

Received 19/06/95; revised 02/09/95; accepted 01/10/95

* Consultant Specialist, Assir Dental Center, P.O. Box 1393, Abha, Saudi Arabia.

* Espe GmbH and Co., Seefeld/Oberbay, Germany.

t Bayer Dental, Berkshire, England.

% Vita Zahnfabrik, Bad Sackingen, Germany.

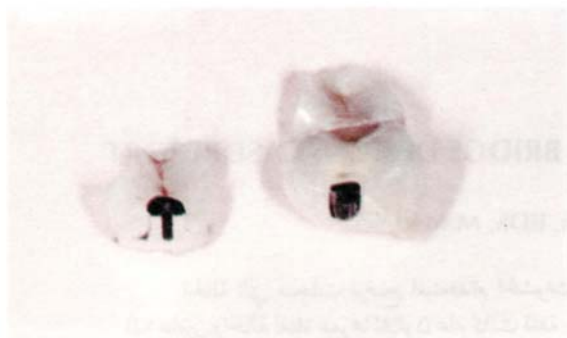


Figure 1. Occlusal view of the fixed-moveable bridge components showing the key and the key of the non-rigid major connector and ceramic tracings with stained fissure.

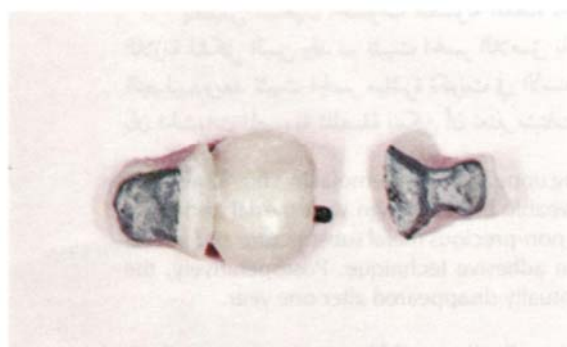

Figure 2. The fitting surfaces of the bridge components showing the metallic sub-structure incorporating the key attachment through the pontic.

consisting a mesial inlay retainer on tooth # 14 which carried the female part of the movable joint. The pontic, on the other hand, carried the male part with the distal inlay retainer on tooth # 16 as shown in Figures 1 and 2. The bridge was cemented with Porcelite® dual cure (untinted) cement [Fig. 3]. This cementation followed the preparation of the fitting surfaces of the bridge by etching with acid and silane from the Mirage FLC[®] kit before applying the Porcelite luting cement. Two weeks later, the recall visit consisted of checking the occlusion, eliminating the high spots, and polishing the restorations. There was post-restoration sensitivity after a one-month recall. At six-month-recall, the restorations were still intact and all teeth were in good health. By the twelfth month the sensitivity had completely disappeared.

© Kerr Manufacturing, USA.
Chameleon Dental Products, USA.

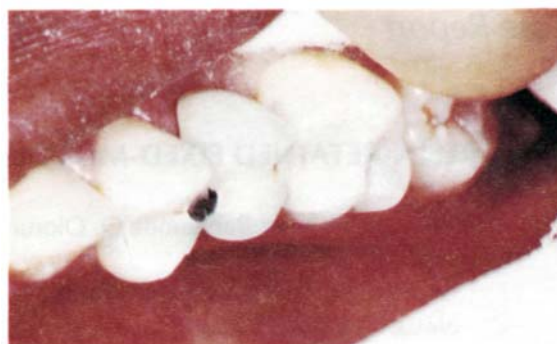

Figure 3. Intraoral view of the bridge immediately after cementation.

Discussion

Similar situations could have been restored with a single implant or conventional bridge design. Full crown preparation of the abutment teeth would have resulted in unnecessary destruction of tooth tissue since minimal tooth reduction is more desirable. As there were intracoronal restorations already present in the abutment teeth, their replacement appeared more conservative. Since this patient appeared well motivated and having a canine-guided occlusion, there was no difficulty in choosing a resin-retained restoration design for her.

A fixed-moveable bridge was considered desirable because of the location of the pontic. The incorporation of a non-rigid connector was done mesially to increase bridge resistance to cementation failure as a consequence of masticatory stresses. Generally, tooth preparation for adhesive retainers are based on the principle of retention by resin bonding instead of frictional resistance. This concept underestimates the significance of frictional resistance which is being used in traditional fixed prosthodontic techniques. Frictional resistance should be included in the resin bonded restoration as much as possible. However, it may be disregarded when sacrificing sound tooth tissue or exposing the dentine is required.¹¹

Conventional inlay castings may exert a wedging effect on the opposing walls of the tooth which is at risk of fracture. If strong cusps on a vital tooth are left, as encouraged by minimal tooth preparation and adhesive techniques, then the risk of tooth fracture is minimized. Vital teeth, which have been restored with composite and ceramic inlays, exhibited a fracture resistance similar to that of the

unprepared teeth.⁴⁵ Improved marginal adaptation and reduced microleakage have also been reported for ceramic inlays.⁶

The patient experienced a post restoration sensitivity for two weeks following cementation of the bridge. Intermittent sharp pain beneath the tooth colored inlays was reported for a few months. This is due to the piezo-electric currents generated beneath such restoration among other factors. However, this was expected to disappear in few months possibly due to short-circuiting penetration of the saliva into the contractional gap left by polymerization shrinkage of the bonding agent.⁷ Post restoration hypersensitivity is therefore not totally unexpected beneath inlay restorations. In a clinical study of 30 cases, Krejci *et al* reported that about 10% had post restoration sensitivity following the provision of composite inlays. Sensitivity disappeared completely after the twelfth month. After two years, the success of this bridge was a noteworthy indication of its durability. It is a rather promising alternative treatment modality for the management of missing upper premolars and similar cases.

Acknowledgement

The author is grateful to Dr. Simon E. Northeast of the Department of Restorative Dentistry, University

of Sheffield, for his interest and support in the management of this patient. Gratitude is also due to the University of Sheffield for the scholarship granted to the author which had given him the opportunity to carry out this work.

References

1. Livaditis GJ. Etched-metal resin-bonded intracoronal cast restorations. Part II: Design criteria for cavity preparation. *J Prosthet Dent* 1986;56(4):389-95.
2. Barrack G. The etched cast restoration - clinical techniques and long-term results. *Quintessence Int* 1993;24(10):701-13.
3. Burke EJ, Qualtrough AJ. Aesthetic inlays: composite or ceramic? *Br Dent J* 1994;176(2):53-60.
4. Jensen ME, Redford DA, William BT, Gardner F. Posterior etched porcelain restorations: an in vitro study. *Compendium* 1987;8(8):615-17,620-22.
5. Dietschi D, Maeder M, Meyer JM, Holz J. In vitro resistance to fracture of porcelain inlays bonded to tooth. *Quintessence Int* 1990;21:823-31.
6. Bergmann P, Noack MJ, Roulet JF. Marginal adaptation with glass ceramic inlays adhesively luted with glycerine gel. *Quintessence Int* 1991;22:739-44.
7. Sjogren G, Bergman M, Mohin M, Bessing C. A clinical examination of ceramic (Cerec) inlays. *Acta Odontol Scand* 1992;50(3): 171-78.
8. Krejci I, Guntert A, Lutz F. Scanning electron microscopic and clinical examination of composite resin inlays/onlays up to 12 months in situ. *Quintessence Int* 1994;25(6):403-90.