



ORIGINAL ARTICLE

# Stability of the mandible after bilateral sagittal split osteotomy: Comparison between positioning screws and plate

Nasser Nooh

Department of Oral and Maxillofacial Surgery, College of Dentistry, King Saud University,  
P.O. Box 60169, Riyadh 11545, Saudi Arabia

Received 21 January 2009; revised 31 January 2009; accepted 11 February 2009  
Available online 29 October 2009

## KEYWORDS

Sagittal split osteotomy;  
Positioning screws;  
Mandible

**Abstract** Relapse is one of the complications of orthognathic surgery. In this study, we compared the stability of mandibular bilateral sagittal split osteotomy by using two different methods of fixation. In *Group 1*, eight patients with prognathic mandible underwent BSSO and set back average of 6.0 mm. The method of fixation was positioning screws. In *Group 2*, eight patients with prognathic mandible underwent BSSO and set back average of 6.0 mm. The method of fixation was plate and monocortical screws. In *Group 3*, eight patients with retrognathic mandible underwent BSSO and advancement average of 6.0 mm. The method of fixation was positioning screws. In *Group 4*, eight patients with retrognathic mandible underwent BSSO and advancement average of 6.0 mm. The method of fixation was plate and monocortical screws. The results showed in terms of advancement that there was no significant difference between the groups after one year. However, in terms of set back, this study showed significant difference.

© 2009 King Saud University. All rights reserved.

## 1. Introduction

The combination of orthodontic treatment and orthognathic surgery is an ideal modality for the treatment of some muscu-

loskeletal deformities such as mandibular prognathism and retrognathism. Mandibular prognathism is one of the first mandibular deformities which were treated by orthognathic surgery (Trauner and Obwegeser, 1957). Different techniques such as intra oral vertical ramus osteotomy (IVRO), extra oral vertical ramus osteotomy (EVRO) or subapical osteotomy and sagittal split osteotomy (SSO) are used for surgical treatment of mandibular prognathism (Chen et al., 2008; Yoshioka et al., 2008; Pangrazio et al., 2001). The bilateral sagittal split osteotomy (BSSO) was first introduced by Trauner and Obwegeser (1957) as a surgical modality to treat mandibular prognathism. This technique was modified by many surgeons like DalPont (1961) and Epker (1977). Furthermore, if the deformity is in both the maxilla and the mandible, the surgeon will

E-mail address: nnooh@ksu.edu.sa

1013-9052 © 2009 King Saud University. All rights reserved. Peer-review under responsibility of King Saud University.  
doi:10.1016/j.sdentj.2009.10.003



Production and hosting by Elsevier

usually combine the procedures, for example, Lefort 1 and BSSO to correct the deformity (Guyuron, 1989). Following orthognathic surgery, mandibular fixation is needed.

There are many different methods of mandibular fixation such as using intra osseous wiring combined with inter maxillary fixation (IMF) which showed significant amount of relapse and patient dissatisfaction, this is called nonrigid fixation (NRF). Another type of mandibular fixation is the three point fixation using positioning screws called rigid fixation (RF). RF technique soon became the standard of care in most cases. Recently, a new technique for RF was introduced, the 2 mm plate fixation with monocortical screws. The changes to rigid fixation added comfort to the patient, quick recovery and additional functions.

The condyle is an important element in selecting the type of fixation. The use of NRF will allow the condyle to settle in the fossa more comfortably. However, previous studies (Nemeth et al., 2000; Feinerman and Piecuch, 1995; Chung et al., 2008) had shown that there is no significant difference in the condylar dysfunction in regard of the method of fixation.

The aim of this study was to evaluate the relapse of the mandible by using plate and monocortical screws versus three positioning screws in BSSO.

## 2. Materials and methods

### 2.1. Subjects

Thirty-two patients ages between 18 and 30 years old (mean age 23 years) were included in the study. Patients were selected from hospitals in Riyadh, Saudi Arabia. All patients underwent pre-orthognathic surgery orthodontic treatment by a consultant in orthodontics.

The exclusion criteria were: any patient who needed bimaxillary procedure, mandibular movement less than 4 mm or greater than 8 mm, or age less than 18 and more than 30 were not included in the study.

The consent of all the patients was obtained according to the standard hospital rule and regulations.

The subjects were randomly divided into four groups:

- Group 1: Eight patients with prognathic mandible underwent BSSO and set back of average 6.0 mm. The method of fixation was positioning screws.
- Group 2: Eight patients with prognathic mandible underwent BSSO and set back of average 6.0 mm. The method of fixation was plate and monocortical screws.
- Group 3: Eight patients with retrognathic mandible underwent BSSO and advancement of average 6.0 mm. The method of fixation was positioning screws.
- Group 4: Eight patients with retrognathic mandible underwent BSSO and advancements of average 6.0 mm. The method of fixation was plate and monocortical screws.

### 2.2. Material

The positioning screws used were 2 mm thickness with 12 mm length. The plates are 2 mm plating system with four screws,

two anteriors with 5 mm length and two posteriors with 7 mm in length (Chung et al., 2008; Chou et al., 2005; Fujioka et al., 2000). The patients with plating were kept in elastic IMF (intermaxillary fixation) for four weeks whereas the positioning screws were kept in IMF for one week.

### 2.3. Method

The bilateral sagittal split osteotomy was done as described by Trauner and Obwegeser (1957) and modified by DalPont (1961) and later by Epker (1977). An incision was made in the retro-molar area and the mandible was exposed. The medial aspect of the ramus was exposed and a monocortical bony cut was made medially and superior to the mandibular canal. A cut was made in the anterior ramus and continued onto the crest of the mandibular area of the third molar. The body of the mandible was exposed. A cut was made at the area between the second and third molar lateral to the mandible extending from the inferior border of the mandible to meet the cuts on the crest. All monocortical cuts were connected.

### 2.4. Statistical analysis

All patients have preoperative lateral cephalometric radiography and postoperative at one week, five weeks, six months and one year. We used the pogonion point in the lateral cephalometric radiographs as the reference point (Van Sickels et al., 1986). All cephalometric radiography of the postoperative was compared to the preoperative one. Statistical analysis was performed using SPSS and ANOVA test.

## 3. Results

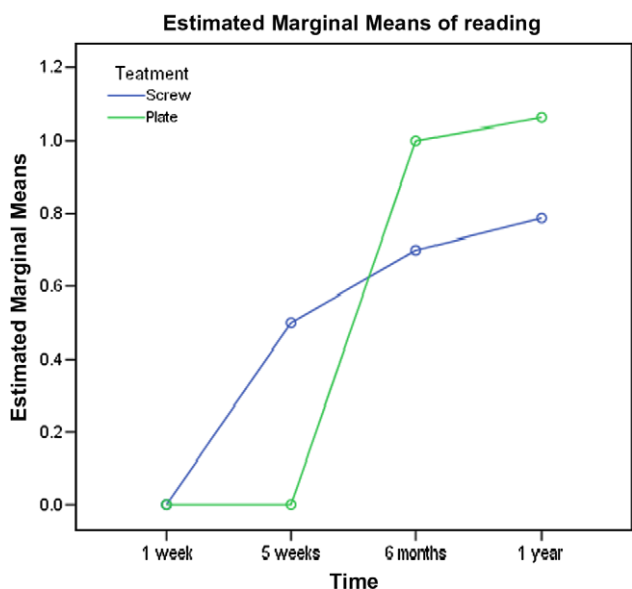
Results showed that in one week, when the patients were kept in elastic IMF, no relapse occurred in all groups (Table 1). The plate and monocortical screws groups showed minimum relapse at five weeks because the patient were in IMF for four weeks. However, after 6 months and one year, the relapse increased in all groups. The maximum relapse was seen in Group 4.

Figs. 1 and 2 illustrated the relapse of all groups in all time intervals. This showed the dramatic increase between 5 weeks and 6 months in all groups. The setback movement one year postoperative had a significant difference in terms of relapse between Groups 1 and 2 ( $P < 0.05$ ) as shown in Table 2. The advancement Groups 2 and 4 showed no significant difference ( $P > 0.05$ ). However, more relapse was seen in advancement compared to the setback.

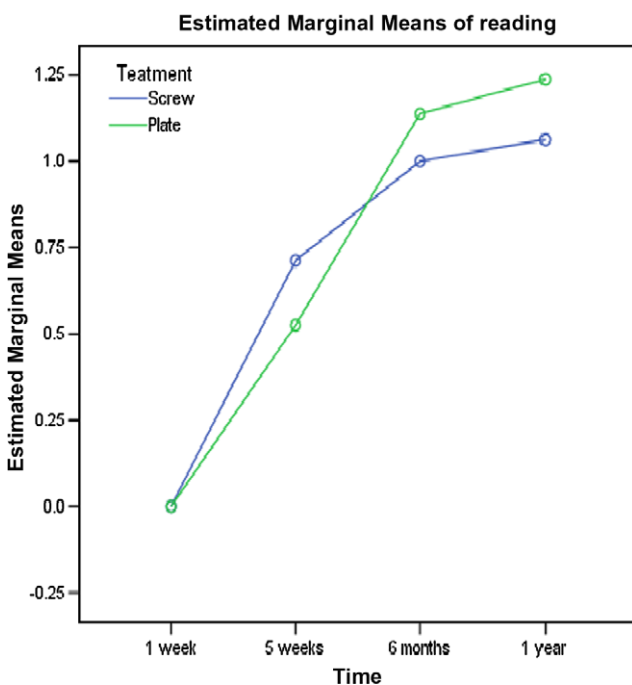
Table 3 illustrated the changes that occurred after one year in Groups 2 and 4. Also a significant difference was found between setback and advancement using plate. We have shown

**Table 1** Relapse using pogonion as reference point.

Groups/ relapse	One week (mm)	Five weeks (mm)	Six months (mm)	One year (mm)
One	0.0	0.5	0.7	0.78
Two	0.0	0.0	1.0	1.06
Three	0.0	0.7	1.0	1.06
Four	0.0	0.5	1.13	1.23



**Figure 1** Graph showing the relapse in Groups 1 and 2 in all time intervals.



**Figure 2** Relapse in Groups 3 and 4 in all time intervals.

**Table 2** The difference between Groups 1 and 2 one year postoperatively.

Treatment	Mean	Standard deviation	95% Confidence interval for mean
Group 1	0.787	0.155	0.6576 (lower bound)
Group 2	1.062	0.213	0.9173 (upper bound)

**Table 3** The difference between Groups 3 and 4 one year postoperatively.

Treatment	Mean	Standard deviation	95% Confidence interval for mean
Group 3	1.062	0.184	0.908 (lower bound)
Group 4	1.23	0.1767	1.216 (upper bound)

that relapse in advancement was more than in the setback, Groups 3 and 4 ( $P < 0.05$ ).

#### 4. Discussion

The etiology of relapse is multi factorial; the condylar position, the musculature and the amount of mandibular movements all play a role in the magnitude of relapse (Joss and Vassalli, 2008).

The technique of BSSO is the most widely used technique in correcting mandibular deformities. However, the IVRO is also used in patients (Chou et al., 2005). In our study, the P point was selected which was most widely used to assess mandibular movements because it is stable and reliable (Van Sickels et al., 1986).

The relapse in one week was zero which was attributed to the function of the IMF. The five weeks were good indicators in most cases as shown in our study. Almost 50% of the relapse occurred in the 5 weeks postoperative group except in Group 2. In our cases, elastic IMF was not used after 4 weeks. Perrott et al. (1994) reported that when they use IMF, mandibular relapse occurred during the period of IMF. Van Sickels (1991) investigated relapse in the mandibular advancement and found that after 6 weeks, around 20% relapse occurred.

Most studies found similar results in terms of relapse in 6 months and one year postoperatively. Joss and Thüer (2008) looked at the relapse after mandibular setback and they found 21% relapse in their study. Kierl et al. (1990) investigated the relapse in the mandibular advancement, they advanced the mandible to an average of 6.7 mm and found relapse of 14%. Frey et al. (2007) showed a similar result of relapse with mandibular advancement. Chung et al. (2008) have shown no significant difference in terms of mandibular relapse regardless of the method of rigid fixation. Furthermore, Chou et al. (2005) looked at relapse in Taiwanese patients after mandibular setback and found that 21% relapse after one year. However, the amount of movement in Chou's study was more than in our study. Eggenesperger et al. (2004) also showed more relapse in advancement up to 30% compared to the setback and concluded that the magnitude of relapse was correlated to the magnitude of surgical movements. Fujioka et al. (2000) concluded that in terms of mandibular relapse, the positioning screws are more rigid.

After one year, our study showed in the setback that the positioning screws gave better results which had statistical significant difference. Other authors (Choi et al., 2000, 2005; Yamashita et al., 2007) had similar amount of movement as in our study and reported in the setback similar relapse. However, they concluded that they did not find any significant difference between the two methods of fixation. Emshoff et al. (2003) found mandibular relapse after one year to be 11.5% in the case of mandibular advancement. Our results were in agreement with Ueki et al. (2007) in the case of mandibular setbacks. Mobarak et al. (2000) performed EVRO to correct the

mandibular position using plate fixation and the results showed that relapse is 10% in setback. However, EVRO is not a cosmetic approach. Some surgeons are using lag screw instead of positioning screw. Watzke et al. (1991) found no difference between this two techniques in terms of mandibular relapse. However, plate and monocortical screws are less damaging to the neurovascular bundle (Fujioka et al., 1999), faster and better nerve function (Hu et al., 2007). In this study, the patients did not show significant changes between 6 months and one year as shown in other studies (Choi et al., 2005).

## 5. Conclusion

The use of positioning screws or plate and monocortical screws with IMF to stabilize the mandible after BSSO in mandibular advancement showed no significant difference in terms of relapse. However, we showed significant difference between the two methods of fixation in terms of setback.

## References

- Chen, C.M., Lee, H.E., Yang, C.F., Shen, Y.S., Huang, Y.C., Lia, S.T., 2008. Intraoral vertical ramus osteotomy for correction of mandibular prognathism long term stability. *Ann. Plast. Surg.* 61 (1), 52–55.
- Choi, B.H., Min, Y.S., Yi, C.K., Lee, W.Y., 2000. A comparison of the stability of miniplate with bicortical screw fixation after sagittal split setback. *Oral Surg. Oral Med. Oral Pathol. Oral Radiol. Endod.* 90 (4), 416–419.
- Choi, B.H., Zhu, S.J., Han, S.G., Huh, J.Y., Kim, B.Y., Jung, J.H., 2005. The need for intermaxillary fixation in sagittal split osteotomy setbacks with bicortical screw fixation. *Oral Surg. Oral Med. Oral Pathol. Oral Radiol. Endod.* 100 (3), 292–295.
- Chou, J.I., Fong, H.J., Kuang, S.H., Gi, L.Y., Hwang, F.Y., Lai, Y.C., Chang, R.C., Kao, S.Y., 2005. A retrospective analysis of the stability and relapse of soft and hard tissue change after bilateral sagittal split osteotomy for mandibular setback of 64 Taiwanese patients. *J. Oral Maxillofac. Surg.* 63 (3), 355–361.
- Chung, I.H., Yoo, C.K., Lee, E.K., Ihm, J.A., Park, C.J., Lim, J.S., Hwang, K.G., 2008. Postoperative stability after sagittal split ramus osteotomies for a mandibular setback with monocortical plate fixation or bicortical screw fixation. *J. Oral Maxillofac. Surg.* 66 (3), 446–452.
- DalPont, G., 1961. Retromolar osteotomy for correction of prognathism. *J. Oral Surg. Anesth. Hosp. D Serv.* 19, 42–47.
- Eggensperger, N., Smolka, W., Rahal, A., Iizuka, T., 2004. Skeletal relapse after mandibular advancement and setback in single-jaw surgery. *J. Oral Maxillofac. Surg.* 62 (12), 1486–1496.
- Emshoff, R., Scheiderbauer, A., Gerhard, S., Norer, B., 2003. Stability after rigid fixation of simultaneous maxillary impaction and mandibular advancements osteotomies. *Int. J. Oral Maxillofac. Surg.* 32 (2), 137–142.
- Epker, B.N., 1977. Modification in the sagittal osteotomy of the mandible. *J. Oral Surg.* 35, 157–159.
- Feinerman, D.M., Picuch, J.F., 1995. Long term effect of orthognathic surgery on the temporomandibular joint: comparison of rigid and nonrigid fixation methods. *Int. J. Oral Maxillofac. Surg.* 24 (4), 268–272.
- Frey, D.R., Hatch, J.P., Van Sickels, J.E., Dolce, C., Rugh, J.D., 2007. Alternation of the mandibular plane during sagittal split advancement: short and long term stability. *Oral Surg. Oral Med. Oral Pathol. Oral Radiol. Endod.* 104 (2), 160–169.
- Fujioka, M., Hirano, A., Fujii, T., 1999. Comparative study of inferior alveolar disturbance restoration after sagittal split osteotomy by means of bicortical versus monocortical osteosynthesis. *Plast. Reconstr. Surg.* 103 (5), 1538–1539.
- Fujioka, M., Fujii, T., Hirano, A., 2000. Comparative study of mandibular stability after sagittal split osteotomies: Bicortical versus monocortical osteosynthesis. *Cleft. Palate Craniofac. J.* 37 (6), 551–555.
- Guyuron, B., 1989. Combined maxillary and mandibular osteotomies. *Clin. Plast. Surg.* 16 (4), 795–801.
- Hu, J., Zhao, Q., Tang, J., Zheng, Z., Qi, M.C., 2007. Changes in the inferior alveolar nerve following sagittal split ramus osteotomy in monkeys: a comparison of monocortical and bicortical fixation. *Br. J. Oral Maxillofac. Surg.* 45 (4), 265–271.
- Joss, C.U., Thüer, U.W., 2008. Stability of hard tissue profile after mandibular setback in sagittal split osteotomies: a longitudinal and long-term follow-up study. *Eur. J. Orthod.* 30 (4), 352–358.
- Joss, C.U., Vassalli, I.M., 2008. Stability after bilateral sagittal split osteotomy setback surgery with rigid internal fixation: a systemic review. *J. Oral Maxillofac. Surg.* 66 (8), 1634–1643.
- Kierl, M.J., Nanda, R.S., Currier, G.F., 1990. A 3-years evaluation of skeletal stability of mandibular advancement with rigid fixation. *J. Oral Maxillofac. Surg.* 48 (6), 587–592.
- Mobarak, K.A., Krogstad, O., Espeland, L., Lyberg, T., 2000. Stability of extraoral vertical ramus osteotomy: plate fixation versus maxillomandibular/skeletal suspension wire fixation. *Int. J. Adult Orthodon. Orthognath. Surg.* 15 (2), 97–113.
- Nemeth, D.Z., Rodrigues-Garcia, R.C., Sakai, S., Hatch, J.P., Van Sickels, J.E., Bays, R.A., Clark, G.M., Rugh, J.D., 2000. Bilateral sagittal split osteotomy and temporomandibular disorder. Rigid fixation versus wire fixation. *Oral Surg. Oral Med. Oral Pathol. Oral Radiol. Endod.* 89 (1), 29–34.
- Pangrazio-Kulbersh, V., Berger, J.L., Kaczynski, R., Shunock, M., 2001. Stability of skeletal class II correction with 2 surgical techniques: the sagittal split ramus osteotomy and the total mandibular subapical alveolar osteotomy. *Am. J. Orthod. Dentofacial. Orthop.* 120 (2), 134–143.
- Perrott, D.H., Lu, Y.F., Pogrel, M.A., Kaban, L.B., 1994. Stability of sagittal split osteotomies. A comparison of three stabilization techniques. *Oral Surg. Oral Med. Oral Pathol.* 78 (6), 696–704.
- Trauner, R., Obwegeser, H., 1957. The surgical correction of mandibular prognathism and retrognathia with consideration of genioplasty. Part I. Surgical procedures to correct mandibular prognathism and reshaping of the chin. *Oral Surg. Oral Med. Oral Pathol.* 10 (7), 677–689.
- Ueki, K., Marukawa, K., Shimada, M., Nakagawa, K., Yamamoto, E., 2007. The use of an intermaxillary fixation screw for mandibular setback surgery. *J. Oral Maxillofac. Surg.* 65 (8), 1562–1568.
- Van Sickels, J.E., 1991. A comparative study of bicortical screws and suspension wires versus bicortical screws in large mandibular advancements. *J. Oral Maxillofac. Surg.* 49 (12), 1293–1296.
- Van Sickels, J.E., Larsen, A.J., Thrash, W.J., 1986. Relapse after rigid fixation of the mandibular advancement. *J. Oral Maxillofac. Surg.* 44 (9), 698–702.
- Watzke, I.M., Tucker, M.R., Turvey, T.A., 1991. Lag screw versus position screw techniques for rigid internal fixation of sagittal osteotomies: a comparison of stability. *Int. J. Adult Orthodon. Orthognath. Surg.* 6 (1), 19–27.
- Yamashita, Y., Mizuashi, K., Shigematsu, M., Goto, M., 2007. Masticatory function and neurosensory disturbance after mandibular correction by bilateral sagittal split ramus osteotomy: a comparison between miniplate and bicortical screw rigid internal fixation. *Int. J. Oral Maxillofac. Surg.* 36 (2), 118–122.
- Yoshioka, I., Khanal, A., Tominanga, K., Horie, A., Furuta, N., Fukuda, J., 2008. Vertical ramus osteotomy versus sagittal split osteotomy: comparison of stability after mandibular set back. *J. Oral Maxillofac. Surg.* 66 (6), 1138–1144.